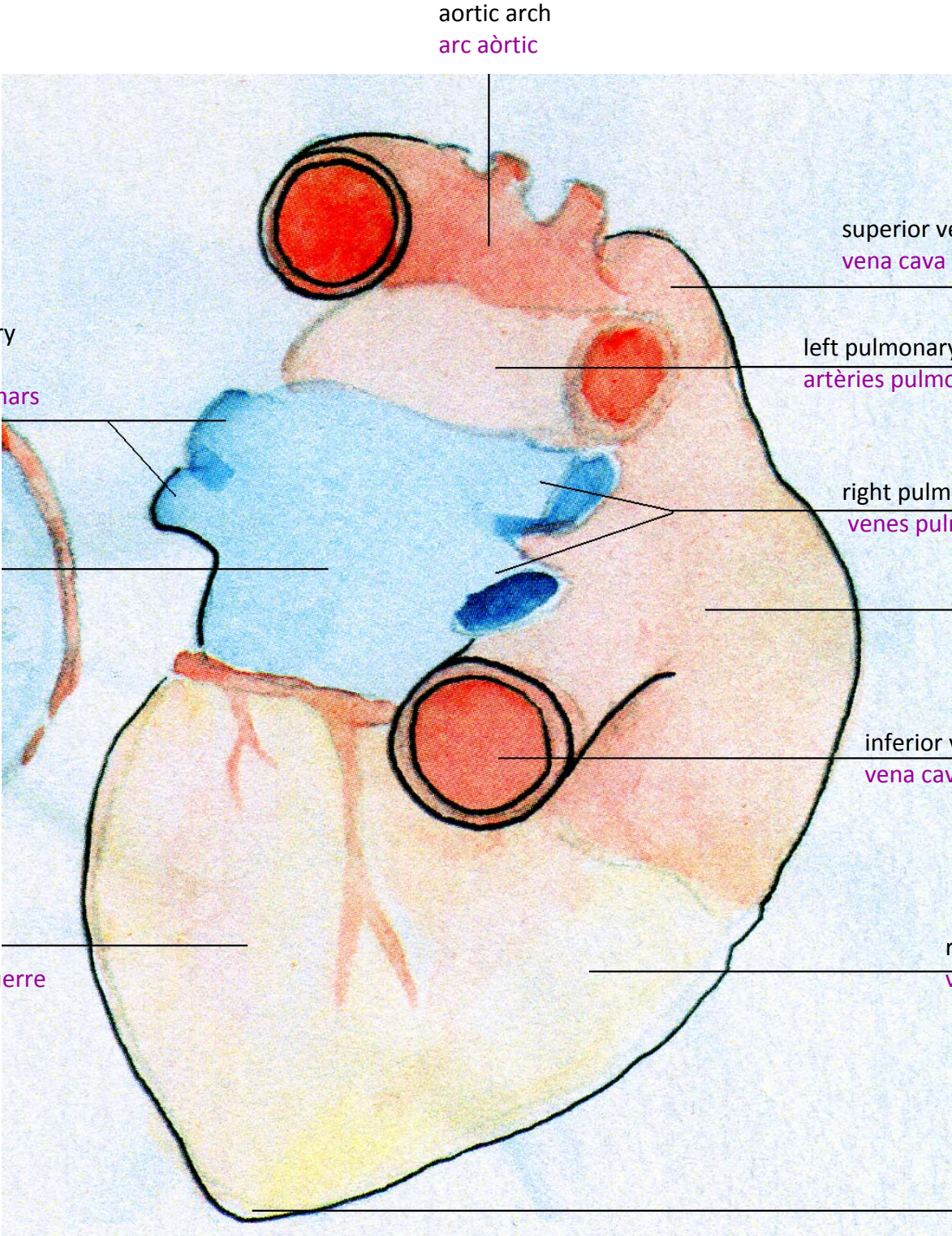


the heart **cor**  
(caudal **caudal**)



aortic arch  
**arc aòrtic**

superior vena cava  
**vena cava superior**

left pulmonary veins  
**venes pulmonars esquerres**

left pulmonary arteries  
**artèries pulmonars esquerres**

left atrium  
**atri esquerre**

right pulmonary veins  
**venes pulmonars dretes**

right atrium  
**atri dret**

inferior vena cava  
**vena cava inferior**

left ventricle  
**ventricle esquerre**

right ventricle  
**ventricle dret**

apex  
**àpex**