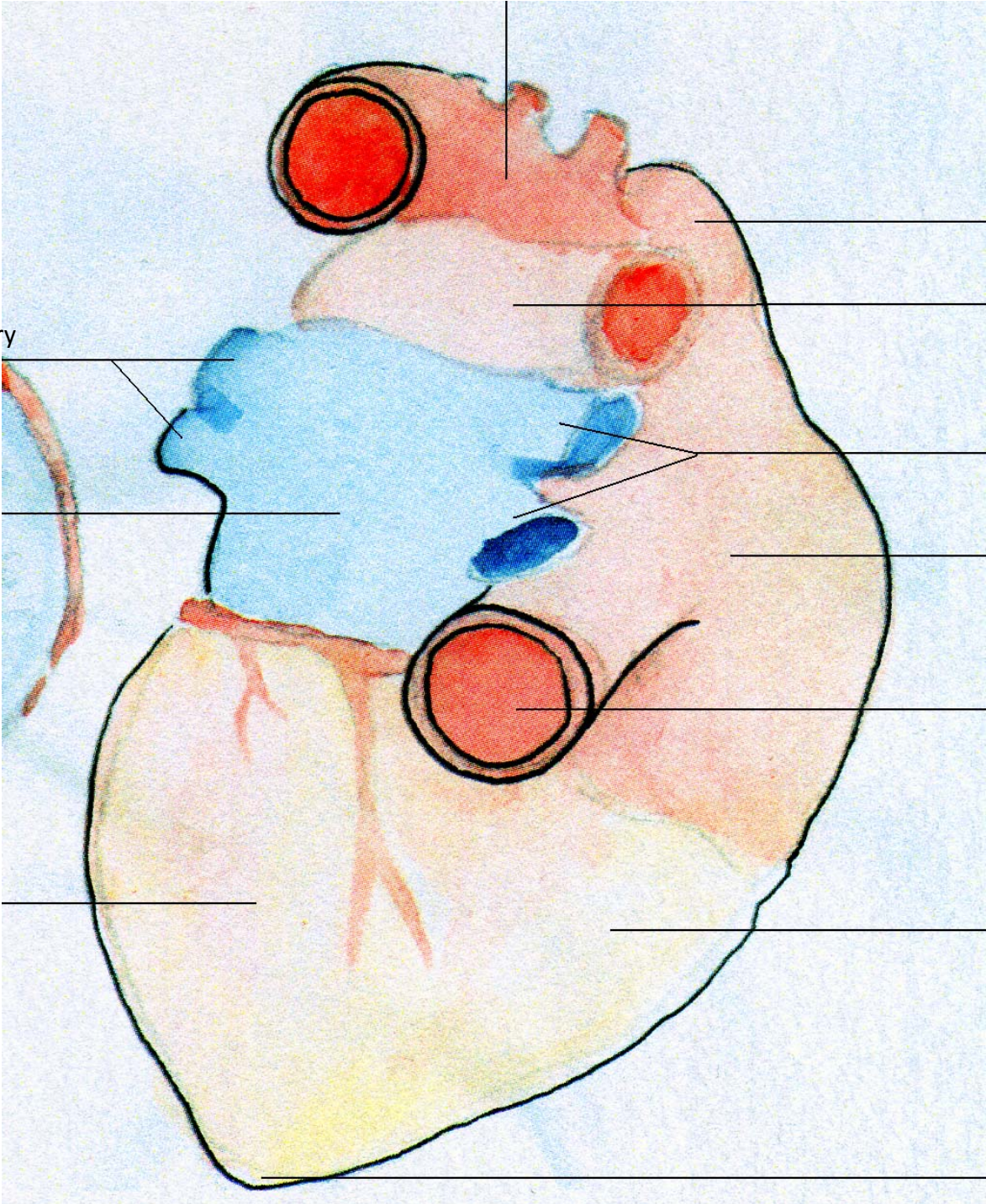


the heart
(caudal)

aortic arch



superior vena
cava

left pulmonary
arteries

right pulmonary
veins

right atrium

inferior vena
cava

right ventricle

apex

left pulmonary
veins

left atrium

left ventricle